

Ameliorative Effect of Ethanolic Extract of Tigernut on Aluminium Chloride Induced Pancreatic Histomorphological Changes on Adult Wistar Rats

Gudaji Abdullahi*, Umar Zailani

Department of Anatomy, Faculty of Basic Medical Sciences, College of Health Sciences, Bayero University, Kano, Nigeria

Email address:

agudaji.ana@buk.edu.ng (GudajiAbdullahi)

*Corresponding author

To cite this article:

Gudaji Abdullahi, Umar Zailani. Ameliorative Effect of Ethanolic Extract of Tigernut on Aluminium Chloride Induced Pancreatic Histomorphological Changes on Adult Wistar Rats. *Advances in Surgical Sciences*. Vol. 9, No. 2, 2023, pp. 17-21.

doi: 10.11648/j.ass.20231101.14

Received: October 1, 2022; Accepted: October 20, 2022; Published: June 27, 2023

Abstract: *Background:* Tiger nut tuber is very common and abundant in Nigeria. Aluminium chloride is the third most abundant metal present naturally on earth crust. *Objective:* The objective of the study was to assess the increase in rate of aluminium chloride exposure and toxicity on the pancreas of adult wistar rats. *Aim:* To evaluate the protective effect of ethanolic extract of tigernut on pancreas of adult wistar rats. *Methods:* In this study twenty five adult rats were used. The animals were grouped into a control group A and treatment groups B, C, D and E. Group A served as control and was administered orally with normal saline, group B was administered orally with 500 mg/kg of aluminum chloride, group C, D and E were administered with 1250 mg/kg of the ethanolic extract of *Cyperus esculentus* only, 500 mg/kg of aluminum chloride followed by 2500 mg/kg of the ethanolic extract of *Cyperus esculentus* and 500 mg/kg of aluminum chloride followed by 3750 mg/kg of the ethanolic extract of *Cyperus esculentus* respectively. The treatment was for six weeks, weights of the rats were recorded weekly. *Result:* The histo-morphology of the pancreas revealed that group A showed the normal pancreatic histo-architecture, group B showed sign of inflammation and paucity of islet cells. Groups C, D and E showed normal pancreatic histomorphology. *Conclusion:* Tissue exposed to aluminum chloride showed fibrosis and inflammation due to toxicity while those exposed to tiger nut therapy showed recovery and regeneration of damaged cells thus indicating ameliorative role of tigernut seed.

Keywords: Ameliorative, Tigernut, Ethanolic Extract, Pancreas, Wistar Rats

1. Introduction

Tigernut is a perennial monocotyledonous plant with a tough, erect, fibrous root [1]. The botanical name of tigernut is *Cyperus esculentus* L. It has many names by [2] depending on the tribe or region where tigernut is cultivated such as *Zulumut*, *Yellow nut sedge*, *Chufa*, *Flat sedge*, *Edible rush nut*, *Watergrass*, *Almond*, *Northern nut grass* and *Nutgrass*. In Nigeria, *Cyperus esculentus* is known as *Ayain* Hausa, *Ofio* in Yoruba and *akihaua* in Ibo tribes respectively. *Cyperus esculentus* grows mainly in the middle belt and northern regions of Nigeria [3]. [4] reported three varieties (black, brown and yellow) that are usually cultivated, that are rich in minerals such as phosphorous, potassium, calcium,

magnesium and iron [5, 6, 7, 8]. Tigernut (*Cyperus esculentus*) belongs to the Division Magnoliophyta, Class-Liliopsida, Order Cyperales and Family Cyperaceae which consists of about 75 genera and over 4000 species [9].

The exocrine secretion that enters the duodenum through the main and accessory pancreatic ducts plays a very important role in the digestion of carbohydrates, proteins and fats [10]. The endocrine pancreas produces two very important hormones, insulin and glucagon. These two hormones are also carried through the portal vein to the liver where they have a profound influence on the metabolism of carbohydrates, proteins and fats [10].

Human and animals always interact with their environment and in turn are exposed to broad spectrum of chemicals and

heavy metals like aluminum, mercury, lead and cadmium which belongs to the most important hazardous substances that can bioaccumulate in the body and collected in tissues with low excretion [11]. Aluminium is an ubiquitous element and the third most abundant element in earth crust [12]. It belongs to class of the minor elements with moderate toxicity on living organism [13].

Tiger nut is highly rich in starch, minerals, oil, and vitamins C, D and E, and is believed to contain all the necessary constituent needed for a balanced diet necessary for bones, tissue repair, muscles, the bloodstream and for body growth and development [14, 15].

Due to its high amounts of nutrients, vitamins, fibre, antioxidants, monounsaturated fatty acids and amino acids, it is believed that tiger nut has some anti-cancer properties [16]. Tiger nut milk has being known for its sugar lowering ability and is suitable for diabetic people and also helps in weight control, due to its content of carbohydrates with a base of sucrose and starch (without glucose), and also its arginine which liberates hormones that produce insulin [17, 18, 19].

Interstitial tissue surrounds lobules of acinar tissue, ducts and islets. The interstitium contains blood vessels, lymphatics, nervous tissue, and stellate cells. White blood cells may infiltrate the interstitium especially during pancreatitis or in reaction to neoplasms. The pancreatic stellate cells (PSC) are specialized connective tissue cells with characteristic structure. They secrete multiple components of the extracellular matrix and are activated by a multiple factors including inflammatory mediators, alcohol and its metabolites, endotoxins and cancer cell-derived factors. Activated PSCs function as fibroblasts, thus contributing to fibrosis associated with chronic pancreatitis and pancreatic duct adenocarcinoma [20].

Exposure of human beings to Aluminium (Al) has been on the rise for a very long period of time [21]. The effects of aluminium are associated with the several environmental elements, industrial chemicals, and food additives. Aluminum (Al) is the most abundant metal in the environment, where it constitutes 8.13% in earth's crust. It is used in daily life as constituent of cooking utensils, medicines, cosmetics, food additives, some foods and aluminum salts used in water purification [22]. Aluminum has toxic effect for both human and animals by entering the body through respiratory and gastrointestinal tracts and accumulates in different tissues such as the liver, kidneys, brain, and heart [23]. The aim of the study was to evaluate the ameliorative effect of ethanolic extract of tigernut on aluminium chloride induced pancreatic histomorphological changes on adult Wistar rats. This was because of the increase in human being exposure to several heavy metals especially aluminium that is highly available in the earth crust and our cooking utensils, food additives, medicines, water purification in our treatment plants and more, and then to see how we could use locally available seeds of tigernut as a herbal medicine in the treatment of the pancreatic cells damage caused by the exposure to the aluminium chloride.

2. Materials and Methods

2.1. Materials

The materials used during this study include; The Tiger nut (*Cyperus esculentus*), Wistar rat (n=25), animal feed, aluminum cages, plastic bottles for drinking water of the rats, syringes (1ml, 2ml and 10ml), digital weighing machine, plain bottles, disposable hand gloves, dessicator, dissection kit, glass slides and cover slip, water bath, refrigerator, electric oven, white plastic cassette, mold, cotton wool, microtome and microscope.

2.2. Chemical and Reagents

The chemicals and reagents used in this study were Aluminum chloride, tween 80, 10% normal saline, distilled water, chloroform, ethanol, xylene, paraffin wax, haematoxylin and eosin, tissue adhesive (albumin), 1% acid alcohol, DPX (Distrene Plasticizer and Xylene).

2.3. Experimental Animals

Twenty five adult Wistar rats (males and females) were purchased from Animal House of Biology Department, Bayero University, Kano and Pathology Department, Aminu Kano Teaching Hospital. The rats were randomly selected and used for this study. They were grouped into group A (control) and treatment groups B, C, D and E.

The rats were grouped according to their body weights. They were kept in the Animal House of Anatomy Department, Bayero University, Kano for two weeks to acclimatized with the environment according to [24].

2.4. Animal Grouping

The animals were grouped into a control group A and the treatment groups B, C, D and E as follows:

Group A: control group received normal saline.

Group B: received 500mg/kg of aluminum chloride only.

Group C: received 1250mg/kg of the ethanolic extract of *Cyperus esculentus* only.

Group D: received 500mg/kg of aluminum chloride+2500mg/kg of the ethanolic extract of *Cyperus esculentus*.

Group E: received 500mg/kg of Aluminum chloride+3750mg/kg of the ethanolic extract of *Cyperus esculentus*.

2.5. The Plant Material

The Tiger nut was bought from KasuwarRimi Kano, market. The plant was identified and authenticated by the Department of Biological Sciences, Bayero University, Kano.

Ethanolic extract of *Cyperus esculentus* was formed using maceration method. LD50 was determined to be 5000mg. The choice of the dosages was based on the fact that at high dose of 5000mg of the ethanolic extract of *Cyperus esculentus*, there was no toxicity on treated rats. Therefore the animals were exposed to selected dosages for period of fourteen (14) days.

2.6. Chemical Substances

The Aluminum chloride was obtained from Biochemistry Department, Bayero University, Kano.

2.7. Animal Sacrifice and Sample Collection

The rats were sacrificed through cervical dislocation, and a midline incision was done through the ventral abdominal wall and the pancreas was harvested immediately and fixed in neutral buffered formalin solution for 24 hours. The tissue was processed using routine histological techniques and stained with hematoxylin and eosin stains for general tissue architecture.

3. Result

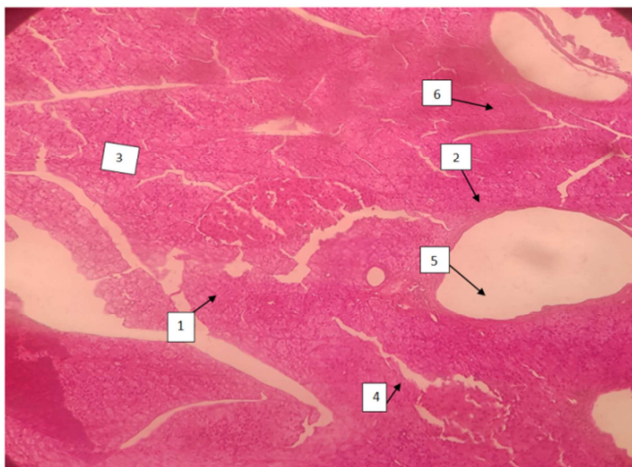


Figure 1. Photomicrograph of pancreas of control group administered with normal saline $\times 100$ showing normal histology (H&E). 1. Islet cells of langerhans, 2. Interlobular duct, 3. Serous acini, 4. Intercalated duct, 5. Vein, 6. Artery. H&E $\times 100$.

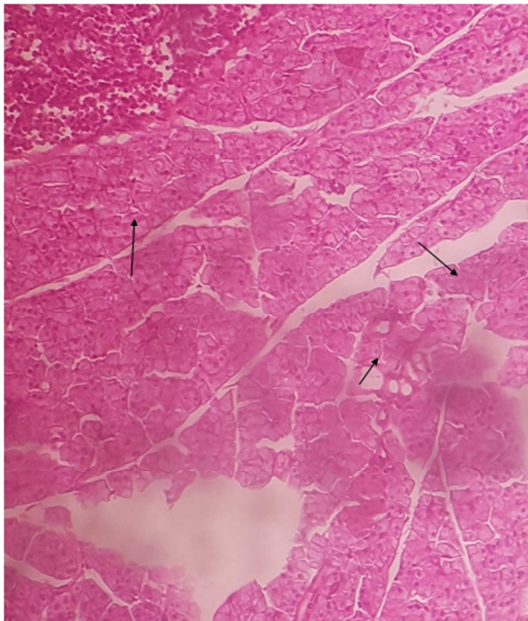


Figure 2. Photomicrograph of pancreas treated with 500mg/kg body weight of Aluminium Chloride showing some Inflammatory cells (H&E) $\times 100$.

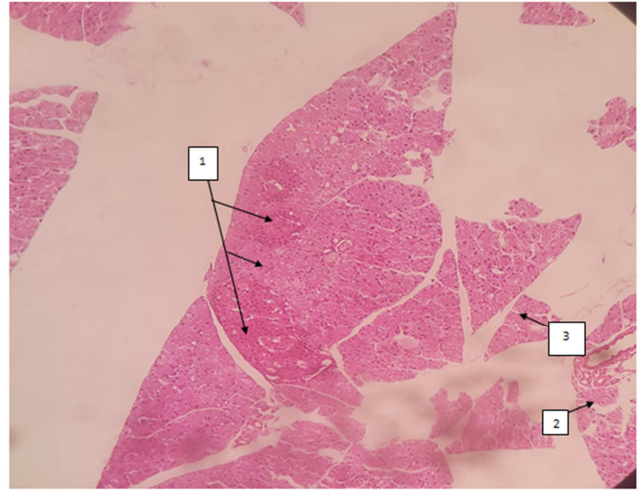


Figure 3. Photomicrograph of pancreas treated with ethanolic extract of *Cyperus esculentus* showing normal histo-architecture with adequate number of islet cells (H&E) $\times 100$. 1. Islet cells, 2. Interlobular duct, 3. Serous acini.

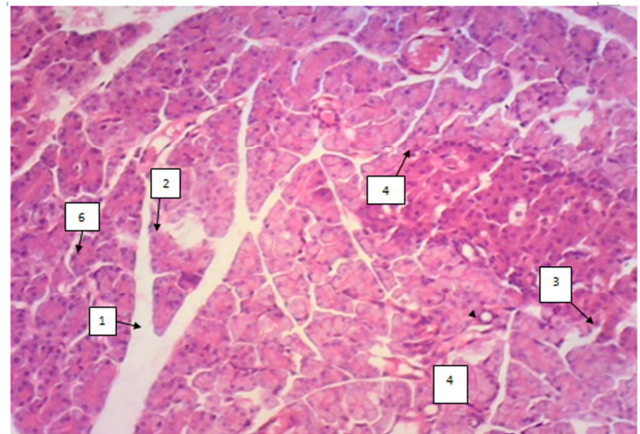


Figure 4. Photomicrograph of pancreas treated with Aluminium Chloride followed by ethanolic extract of *Cyperus esculentus* showing normal histo-architecture (H&E) $\times 100$. 1. Septa, 2. Artery, 3. Islet cells, 4. Vein, 5. Intercalated duct, 6. Serous acini.

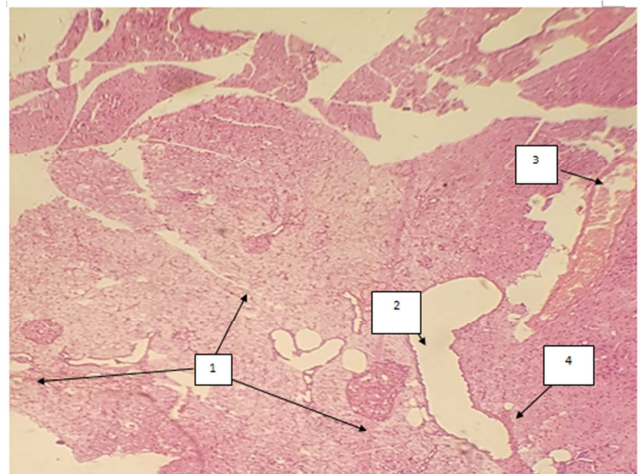


Figure 5. Photomicrograph of pancreas treated with Aluminium Chloride followed by ethanolic extract of *Cyperus esculentus* showing normal histo-architecture (H&E) $\times 100$. 1. Islet cells of langerhans, 2. Interlobular duct, 3. Artery, 4. Interlobular connective tissue septa.

4. Discussion

Study had shown that plasma glucose levels were significantly elevated in rats fed with $AlCl_3$ for 60 days when compared with the normoglycemic group. The increase in blood glucose level of about 58% was due to pancreatic islet damage caused by $AlCl_3$ -induced oxidative damage. This buttress the present study were inflammatory cells were observed in rats treated with aluminium chloride showing necrosis or damaging of pancreatic islet cells [25].

It was observed that rats treated with Aluminium chloride at 50mg/kg for 30 days had significantly increased fasting blood glucose (FBG), initial elevation of serum insulin and insulin resistance at 10-20 days of treatment, followed by a decline in serum insulin level by 30 days of treatment when pancreatic islet damage was reported. Thus, groups treated with aluminium chloride alone will have pancreatic islet damage in line with [26]. However, groups that were treated with tigernut ethanolic extract, will recover from the damage due to regeneration of pancreatic islet cells with subsequent decrease in glucose level. [26]

The histology of group which was administered 1250mg/kg body weight of ethanolic extract of *Cyperus esculentus* alone revealed that morphologically the pancreas was normal, and there was adequate number of islet cells. This is because tiger nut has health benefits because of its high content of soluble glucose and oleic acid, along with high energy content (starch, fats, sugars and proteins), which are rich in minerals such as phosphorous, potassium, calcium, magnesium and iron [15].

The result of the histology of groups treated with 500mg/kg of Aluminium chloride followed by 2500mg/kg and 3750 mg/kg of the ethanolic extract of *Cyperus esculentus* was observed to be normal, which is documented that a systematic study of three extracts of Tiger nut indicates that the mean weights of the animals increased. Tiger nut milk has being known for its sugar lowering ability, and it can be taken by diabetics for its low-glycemic carbohydrates (mainly starch) and arginine content which liberates hormones that produce insulin [17], and blood glucose level decreased significantly in concentration dependent manner [14].

5. Conclusion

In conclusion, the histological changes observed in this study suggested that the intake of Aluminium Chloride has some effect on pancreas, and it was observed that ethanolic extract of *Cyperus esculentus* administered to the treatment group has reverse the effect of the Aluminium Chloride.

References

- [1] Bamishaiye, E. I. and Bamishaiye, O. M. (2011). Tigernut. Asaplant, its derivative and benefits. *African Journal of Food, Agriculture and Nutritional Development*, 11 (5): 5157-5170.
- [2] Sanchez-Zapata, E., Fernandez-Lopez, J. and Angel P. J. (2012). Tigernut (*Cyperus esculentus*) commercialization: health aspects, composition, properties, and food applications. *Comprehensive Reviews in Food Science and Food Safety*. 11 (4): 36677.
- [3] Okafor, J. N. C., Mordi, J. I., Ozumba, A. U., Solomon, H. M. and Olatunji, I. (2003).
- [4] Umerie, S. C. and Enebeli, J. N. (1997). Maltcaramel from the nuts of *Cyperus esculentus*. *Journal of Biological Resources and Technology*, 8: 215-216.
- [5] Belewu, M. A. and Belewu, K. Y. (2007). Comparative physico-chemical evaluation of tiger nut, Soybean and coconut milk source. *International journal of Agriculture and Biology*, 9: 785-787.
- [6] Oladele, A. K., K. and Aina, J. O. (2007). Chemical composition and functional properties of flour from two varieties of tiger nut (*Cyperus esculentus*). *African Journal of Biotechnology* 6 (21): 2473-2476.
- [7] Arafat, S. M., Gaafar, A. M., Basuny, A. M. and Nassef S. L. (2009). Chufa tubers (*Cyperus esculentus*) As a new source of food. *World Applied Sciences Journal*, 7 (2): 151-156.
- [8] Dhonha, K., Diana, A. A., Mokhtar, Z. & Iciar, A. (2016). Review on *Cyperus esculentus*: from food safety to pharmacotherapeutics. *International Journal of Pharmaceutics*, 6 (2): 71-81.
- [9] Muhammad, N. O., Bamishaiye, E. I., Bamishaiye, O. M., Usman, L. A., Salawu, M. O., Nafiu, M. O., and Oloyede, O. B. (2011). Physicochemical properties and fatty acid composition of *Cyperus esculentus* (Tigernut) tuber oil. *Bioresearch Bulletin*. 5: 51-54.
- [10] Singh, V., (2014). Textbook of Anatomy Abdomen and Lower limb. Elsevier. Pp 5.
- [11] Ali, O. I. and Amin, I. M. (2006). Toxicological appraisal of some heavy metals level in water of treated with lead acetate. *International Journal of Drug Development and Research*, 20-13.
- [12] Verstraeten, S. V., Aimo, L. and Oteiza, P. I. (2008). Aluminum and lead: molecular mechanisms of brain toxicity, *Archives of Toxicology*, 82 (11) 789-802.
- [13] Campbell, A., (2002). The potential role of aluminium in Alzheimer's disease. *Nephrology, Dialysis and Transplantation*, 17 suppl. 2 (2): 17-20.
- [14] Chukwuma, E. R., Obioma, N. and Christopher, O. I. (2010). The phytochemical composition and some biochemical effects of Nigerian tigernut (*Cyperus esculentus* L.) tuber. *Pakistan Journal of Nutrition*. 9 (7): 709-15.
- [15] Mason, D Tiger Nuts In: http://www.nvsuk.org.uk/growing_show_vegetables_1/tiger_nut.php2005. Accessed December, 2009.
- [16] Seyran, E. A. and Thong, M. O. (2017). Tigernut (*Cyperus esculentus*): Some natural anticancer drug? Brief Review of existing literature. *Euromediterranean Biomedical Journal*, 12 (19): 91-94.
- [17] Alegria-Toran, A. and Farre-Rovira, R. (2003). Horchata y salud: Aspectos nutricionales y dietéticos. In: Fundación Valenciana de Estudios Avanzados, editor. Jornada Chufa y Horchata: Tradición y Salud. Valencia, Spain: Consellería de Agricultura, Pesca y Alimentación. p. 55-70.

- [18] Martinez-Valls, J. F. (2003). Horchata y Salud: Posibles beneficios de la horchata de chufa en la prevención de la arteriosclerosis. In: Jornada Chufa y Horchata: Tradición y Salud, editor. Fundación Valenciana de Estudios Avanzados. Valencia, Spain: Consellería de Agricultura, Pesca y Alimentación. p. 87-94.
- [19] Chevallier, A. (1996). The Encyclopedia of medicinal plants. Dorling Kindersley Press London. 48-51.
- [20] Mekapogu, A. R., Pothula, S. P., Pirola, R. C., Wilson, J. S. and Apte, M. V. (2020). Pancreatic Stellate Cells in Health and Disease. The Pancreapedia: Exocrine Pancreas Knowledge Base. DOI: 10.3998/panc.2020.08.
- [21] Yokel, R. A. and Mc Namara, P. J. (2001). Aluminum toxicokinetics: an updated mini review. *Pharmacological Toxicology*, 88: 159-167.
- [22] Kumar, V., Bal, A., and Gill, K. D. (2009). Susceptibility of mitochondrial superoxide dismutase to aluminium induced oxidative damage. *Tox.*, 255 (3), 117-123.
- [23] Reiter, R. J., Tan, D. X., Terron, M. P., Flores, L. J., & Czarnocki, Z. (2007). Melatonin and its metabolites: New findings regarding their production and their radical scavenging actions. *Acta Biochimica Polonica-English Edition*, 54 (1): 1.
- [24] Grover, J. K., Yadav, S. P. and Vats, V. (2002). Medical plants in India with anti-diabetic potential. *Journal of Ethnopharmacology*, 81: 81-100.
- [25] Kalaiselvi, A., Aadhinath, Reddy, G. and Ramalingam, V. (2015). Ameliorating effect of ginger extract (*Zingiber officinale* Roscoe) on liver marker enzymes, lipid profile in aluminium chloride induced male rats. *International Journal of Pharmaceutical Sciences and Drug Research*, 7: 52-8.
- [26] Wei, Q., Yan, X. X., Ma, Z. X., Ou, Y. and Jing, S. Q. (2008). Extraction and analysis of cyperus esculentus oil in Xinjiang. *Food Science Technology*, 35: 226.